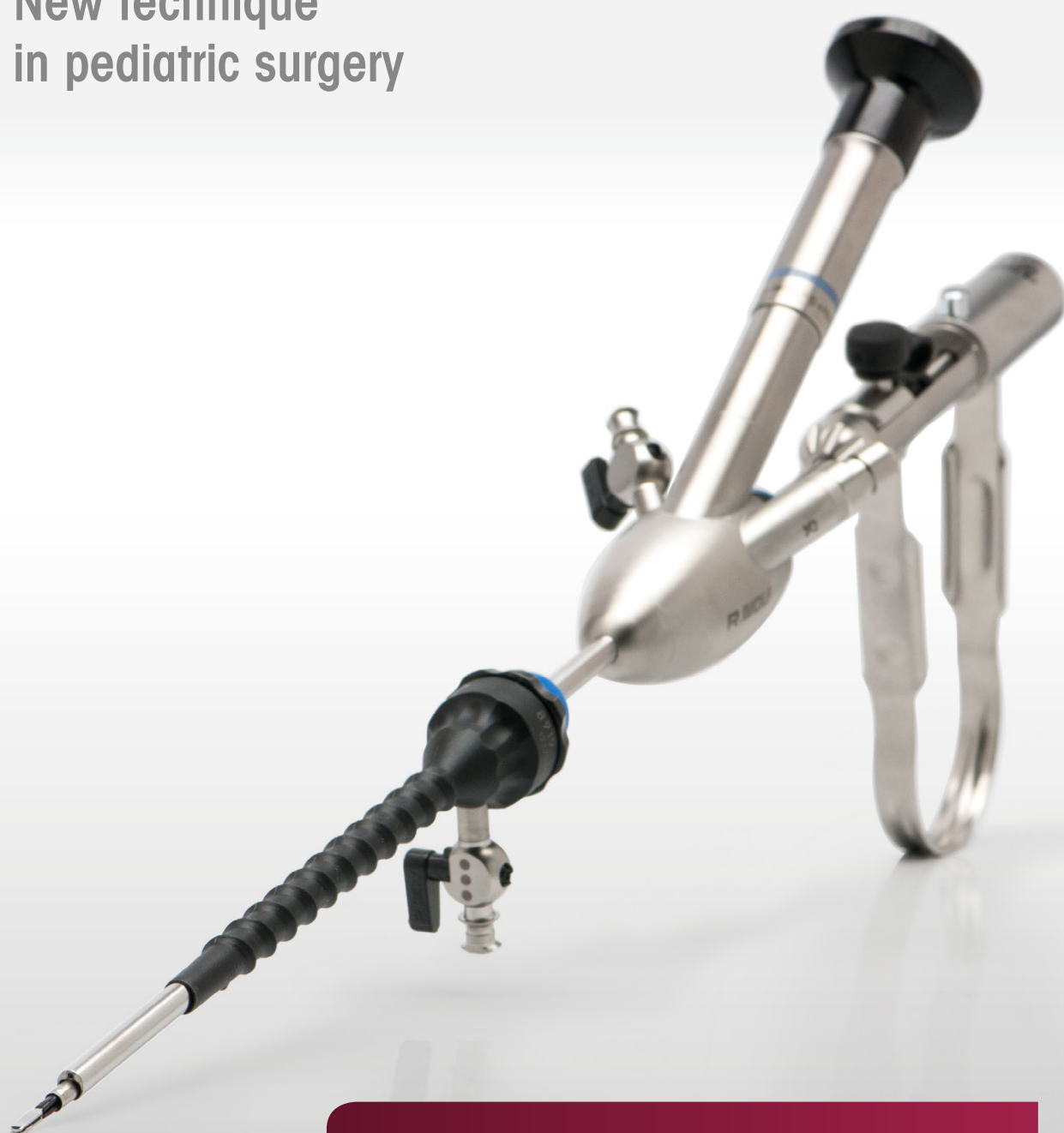

New technique  
in pediatric surgery




## Laparoscopic Single-channel Varicocele Dissection (LEVD)

Technique · Instrument Set · Implementation

# Laparoscopic Single-channel Varicocele Dissection (LEVVD)



PD Dr. med. Ulf Bühligen  
Leipzig University Hospital  
Hospital and Clinic for Pediatric Surgery  
ulf.buehligen@uniklinik-leipzig.de



The technique presented below is a new surgical procedure in pediatric surgery. By contrast with previous laparoscopic procedures, the surgeon only uses one port through which the telescope and instrument set can be inserted. A compact Operation Set was created for this innovative method in the course of cooperation between PD Dr. med. Ulf Bühligen and Richard Wolf.

## Indication

Varicocele testis occurs in approximately 5 - 10 % of young children during the growth phase. The varicocele is mainly located on the left-hand side. The cause is regarded as increased hydrostatic pressure with impaired drainage in the testicular veins where they join the left renal vein.

Clinically the patient presents with thickened venous convolutes in the funicular part. There may also be a dragging ache in the relevant groin region.

## Diagnosis

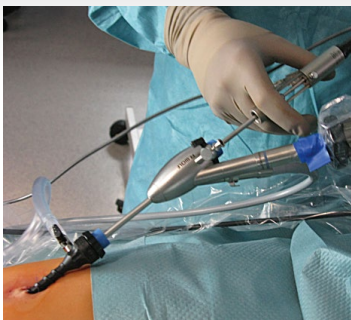The diagnosis includes clinical investigation, ultrasound of both testicles with a comparison of both sides and Doppler vascular imaging with Valsalva's maneuver.

Dilatation of the network of testicular veins with verification of reverse blood flow within one second provides the indication for surgical intervention.

## Method

The various procedures for varicocele surgery are directed toward preventing flow or closing off all malfunctioning veins. Laparoscopic transabdominal vascular transection is currently the intervention of choice.

We have selected the laparoscopic, one-hand single-channel technique (individual trocar technique, 5.5 mm operation laparoscope with 3.5 mm working channel) in order to reduce the surgical trauma and provide a "scarless" method. The laparoscope is easy to manipulate with a convenient, clearly structured 3.5 mm instrument set.



### Instrument set

Specially developed bipolar forceps are required for vascular dissection (with appropriate bipolar generator). A bipolar intervention allows a localized current to be applied to a small area and avoids compromising the neighboring structures.

The option remains of expanding the intervention by using additional 3.5 mm working trocars and continuing to work with the same instrument set without restrictions. A suction and irrigation function maintains visibility in the surgical field.

### Result / Assessment

The intervention is carried out as an out-patient procedure and is well tolerated by all patients. The 5 mm longitudinal incision in the patient's navel leaves no visible scar behind. No wound healing disturbances or cheloid formation have been observed to date in the area of the scar. No neurological disturbances have been identified in the skin region during the course of post-operative follow-up checks, and no hydrocele has occurred. The ultrasound examinations comparing both sides showed good blood supply and development for the testes in all patients.

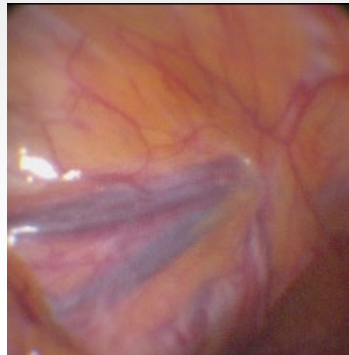# Laparoscopic Single-channel Varicocele Dissection (LEVD)

## Initial preparation

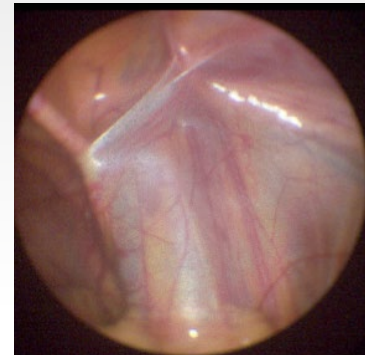
Local application of 2 ml 1 % Carbostesin. The skin incision is a longitudinal incision in the navel (mini-laparotomy). Gas insufflation up to 8 mm Hg is carried out via the 5.5 mm trocar. A 5.5 mm operating laparoscope with integrated 3.5 mm working channel (Richard Wolf) is used. Other access passages and working trocars are not needed.

## Assessment and positioning

The abdomen is assessed, the varicocele side and the opposite side are inspected, the ductus deferens is identified. The patient is positioned slightly inclined to the right in head-down position.



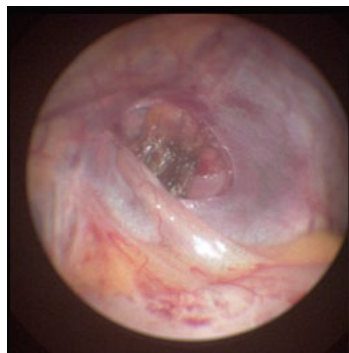Assessment left: Enlarged



Assessment right: Normal findings

## 1. Incision

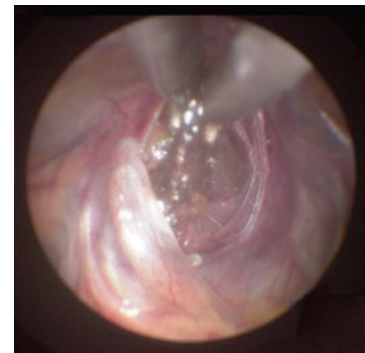The parietal peritoneum is opened using 3.5 mm scissors approximately 2 cm before the inner inguinal ring transverse to the direction of the vessels.



1. Incision

## 2. Preparation

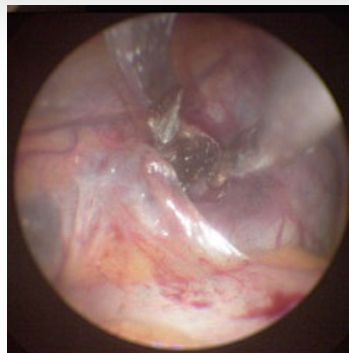
The dissector is used to expose the vessels (veins and artery). Bipolar grasping forceps facilitate coagulation of all visible vessels (veins and artery).



2. Preparation

## 3. Coagulation

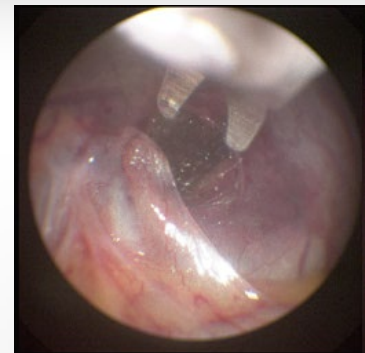The coagulation section should be at least 5 mm. Slightly raising the vessel branch avoids damaging structures of the abdominal wall with the bipolar current flow.



3. Coagulation

## 4. Dissection

The scissors can then be used to safely resect the entire vessel. If the inspection reveals further vessels, this procedure is repeated.

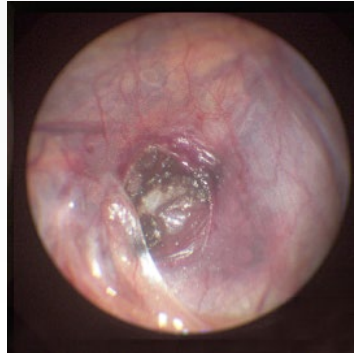

4. Dissection

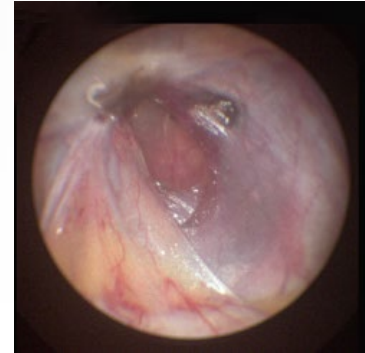

### 5. Completion

The operation is concluded with complete vessel dissection and visible distance between the vessels.



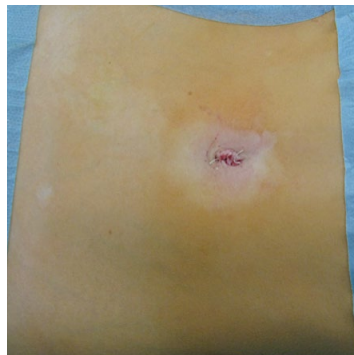
5.1 Partial dissection



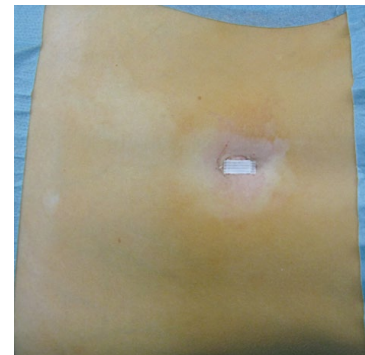
5.2 Complete dissection

### 6. Wound closure

We use 3 x 0 Vicryl threads single button to close the peritoneum at the navel. We suture the main wound with 4 x 0 Vicrylrapid threads. We use short tension tapes positioned longitudinally over the wound as a wound dressing.



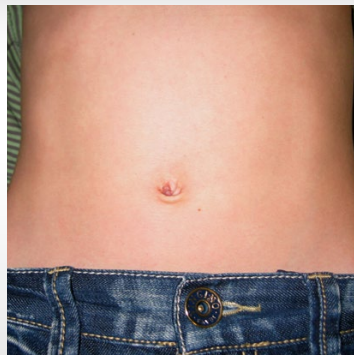6.1 Wound closure



6.2 Wound dressing

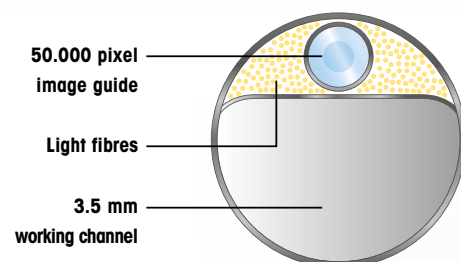
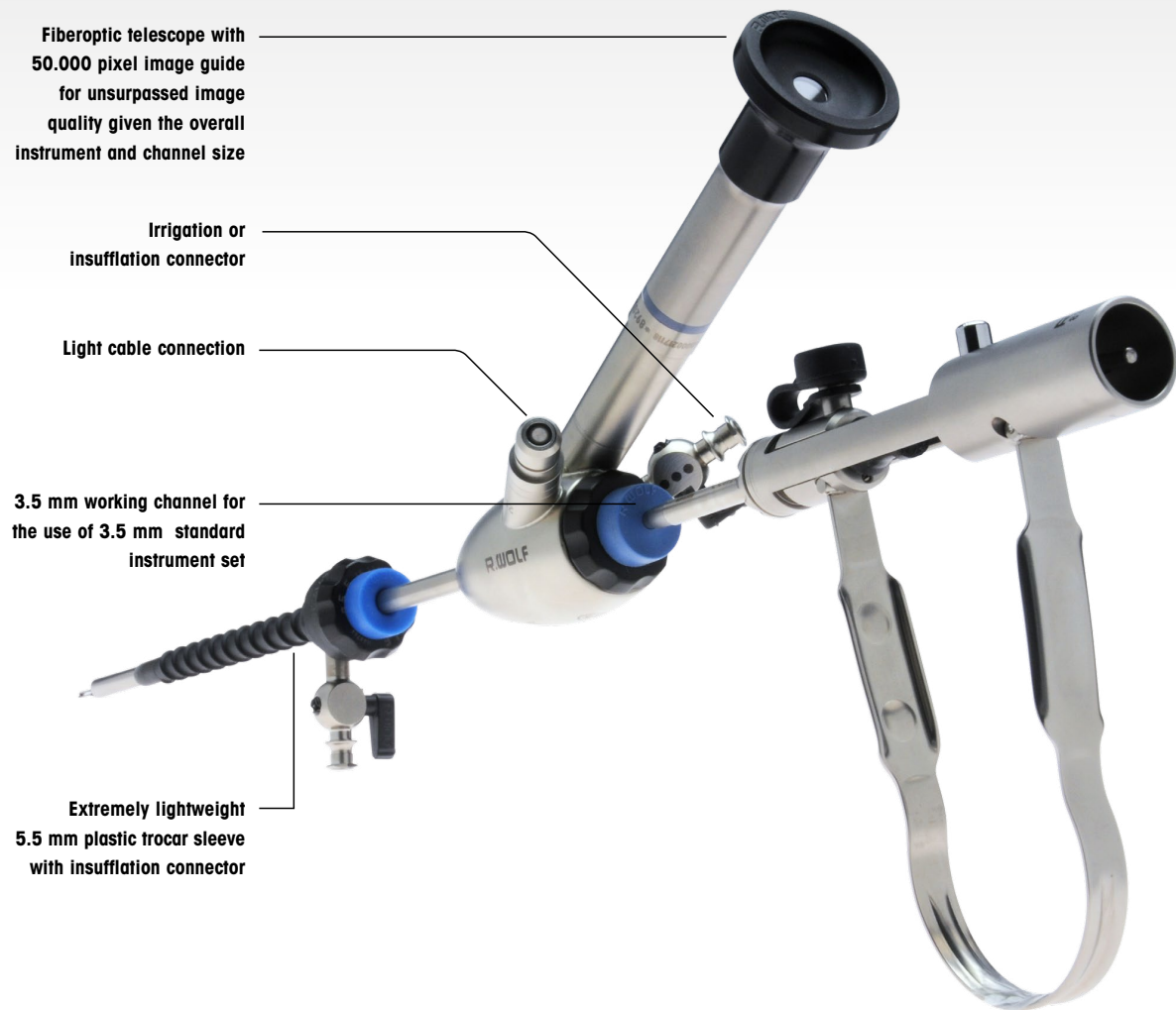
### 7. Healing

After one week, no scar can be seen.



7. One week p.o.

# Laparoscopic Single-channel Varicocele Dissection (LEVD)



Newly designed bipolar jaw insert: specially offset jaw sections at the distal end provide reliable grip




### 5.5 mm Surgical Laparoscope Set

comprising:

Surgical laparoscope with 3.5 mm working channel, 0° viewing direction, silicate image guide (8920.401), seal (8920.311), seal cap (15176.020), working length 215 mm ..... 8920.4011

**Replacement membrane seals, yellow,**  
10 units..... 89.103

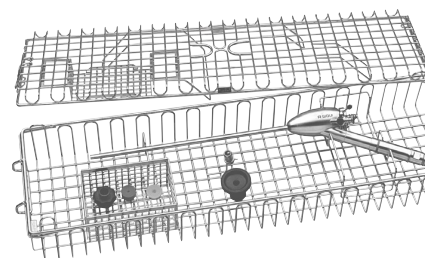


### Fiber light cable

2.5 mm, 2.3 m set.....806625231

**Reprocessing basket**  
for machine reprocessing  
and sterilization,

Dimensions (W x L x H):  
131,5x471,5x74 mm .....38044.211



### Self-retaining plastic trocar sleeve,

5.5 mm, WL 105 mm, autoclavable,  
with insufflation stopcock,  
incl. membrane valve  
89.103 (10 units) ..... 8919.353  
For introduction:



### Trocar,

conical with blunt tip .....8919.3511



### Trocar,

conical with sharp tip .....8919.3512



### Trocar,

with pyramid-shaped tip .....8919.3513












### Bipolar forceps

3.5 mm, cpl.,  
WL 305 mm .....8391.743



# Laparoscopic Single-channel Varicocele Dissection (LEVD)

		Knob attachment	Handle			
<b>ERAGON<sup>axial</sup></b>						
All jaw inserts and sheaths can also be combined with <b>ERAGONaxial</b> .		autoclavable	with lock, without HF	without lock, with HF	with lock, with HF	with lock, without HF, not rotatable
	Type	8988	83930082	83930083	83930084	83930085

Jaw insert		Sheath, ø 3.5 mm		Handle			Complete instrument • Jaw insert • Sheath • Handle
		insulated	uninsulated				
<b>ERAGON<sup>modular mini</sup></b>							
		WL 330 mm		with lock, without HF	without lock, with HF, mono	with lock, with HF, mono	
	Type	8391933	8391934	83930072	83930073	83930074	Type
<b>Scissors "Metzenbaum"</b>	 fine serrated, curved, double-action	8391224	•		•		83912247
<b>Hook scissors</b>							
 single-action	8391227	•			•		83912277
<b>Grasping and dissecting forceps</b>	 curved left, double-action	8391207	•			•	83912077
<b>Universal grasping forceps</b>							
 double-action	8391209		•	•			83912097
<b>Atraumatic grasping forceps</b>	 fenestrated, double-action	8391208	•	•			83912087
<b>Grasping forceps "Babcock"</b>							
 double-action	8391210		•	•			83912107

For further ERAGONmodular instruments see brochure "ERAGONmodular mini" B 796.